



About Science Prof Online PowerPoints

- Science Prof Online (SPO) is a free science education website that provides science-related articles, images, and virtual classrooms. The site is designed to be a helpful resource for students, educators, and anyone interested in learning about science.
- The SPO Virtual Classrooms offer many educational resources, including practice test questions, review questions, lecture PowerPoints, video tutorials, sample assignments and course syllabi.
- The SPO PowerPoints, such as this one, can be found in different formats such as the fully editable PowerPoint, the slideshow and a video tutorial. Please email me at alicia@scienceprofonline.com if a format you need is not available.
- Images used in the PowerPoints, video tutorials, and on the SPO website are, wherever possible, credited and linked to their source. Any words underlined and appearing in blue, on the website or in the PowerPoints are links that can be clicked on for more information.
- Several helpful links to fun and interactive learning tools are included on the Smart Links slide, near the end of the lecture.

Alicia Cepaitis MS
Chief Creative Nerd
Science Prof Online

Tami Port, MS
Creator of Science Prof Online
[Science Prof Online](http://ScienceProfOnline.com)
email: info@scienceprofonline.com

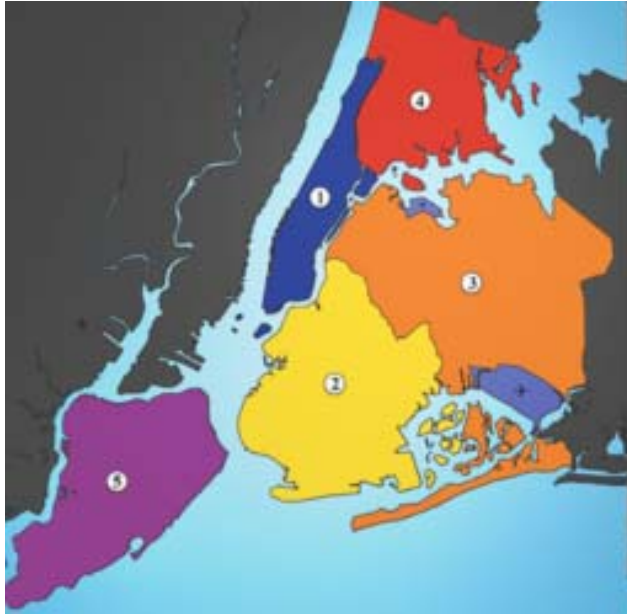Anatomy Lecture Series

1

Human Body Orientation

Part 2: Body Directions

How do we describe the location of one part of the body compared to another part of the body?



Red: Bronx
Blue: Manhattan
Orange: Queens
Yellow: Brooklyn
Purple: Staten island

- Directional terms are used to explain exactly where one body part is compared to another body part or body structure

- Directional terminology is similar to map coordinates.

NYC Map, J.Schorzman:<http://tinyurl.com/c4lwkz>

- Staten island (purple) is **inferior and lateral** to Manhattan (blue) in anatomical terms as Staten Island is South and West of Manhattan in map terms.


- Queens (orange) is superior to Brooklyn in anatomical terms as Queens is North of Brooklyn in map terms.

Superior or cranial

Toward the head end or the upper part of a structure.

A superior structure is above another structure

(black arrow)



Inferior or caudal

Away from the head end or lower part of a structure.

An inferior structure is below another structure

(white arrow)

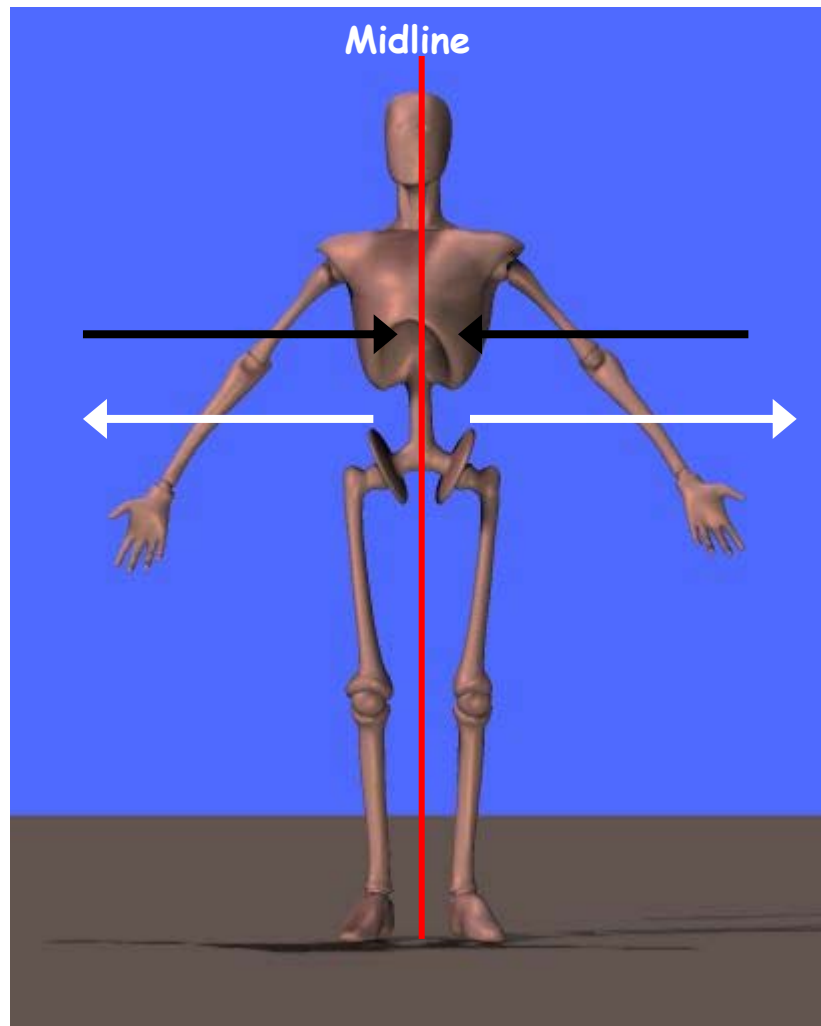
The hips are Inferior to the head and Superior to the knees.

Medial

Toward or at the midline of the body

On the inner portion of the body

(black arrows)



Lateral

Away from the midline of the body

On the outer portion of the body

(white arrows)

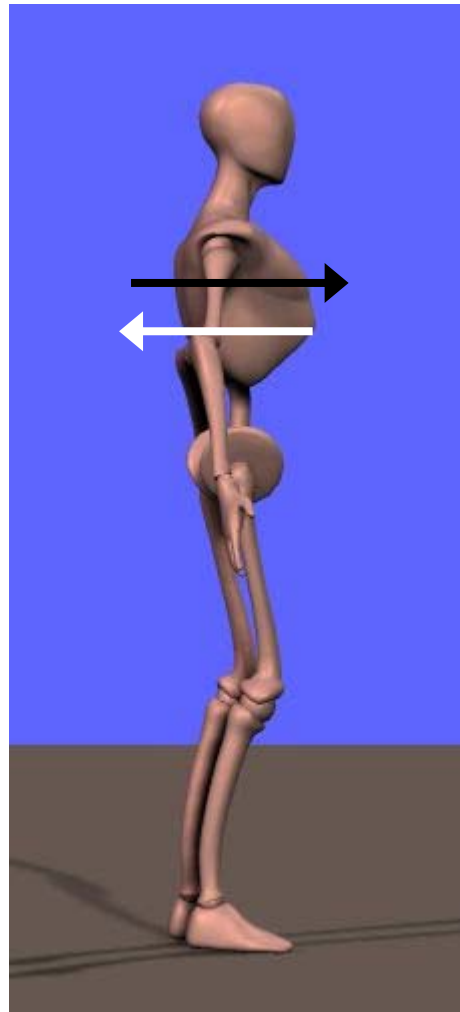
The navel is Medial and Superior to the hips and the shoulders are Lateral and Superior to the navel.

Anterior or ventral

These two terms are interchangeable in humans but not in four-legged animals

Toward the front or in front of another structure

(black arrow)



Posterior or dorsal

These are also interchangeable in humans but differently used in four-legged animals

Toward the back or in back of another structure

(white arrow)

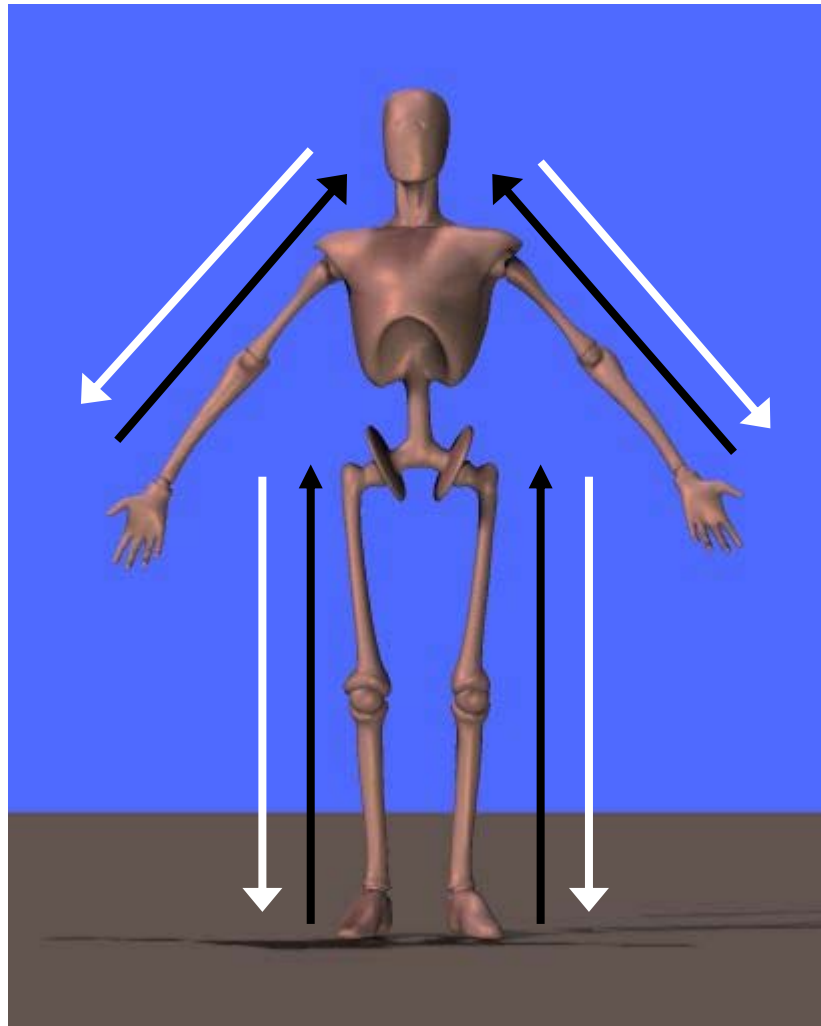
The spine is Posterior to the heart and the heart is Anterior to the ribs.

Proximal

Closer to the origin of a body part or the attachment of a limb

Not usually used for the trunk of the body

(black arrows)



Distal

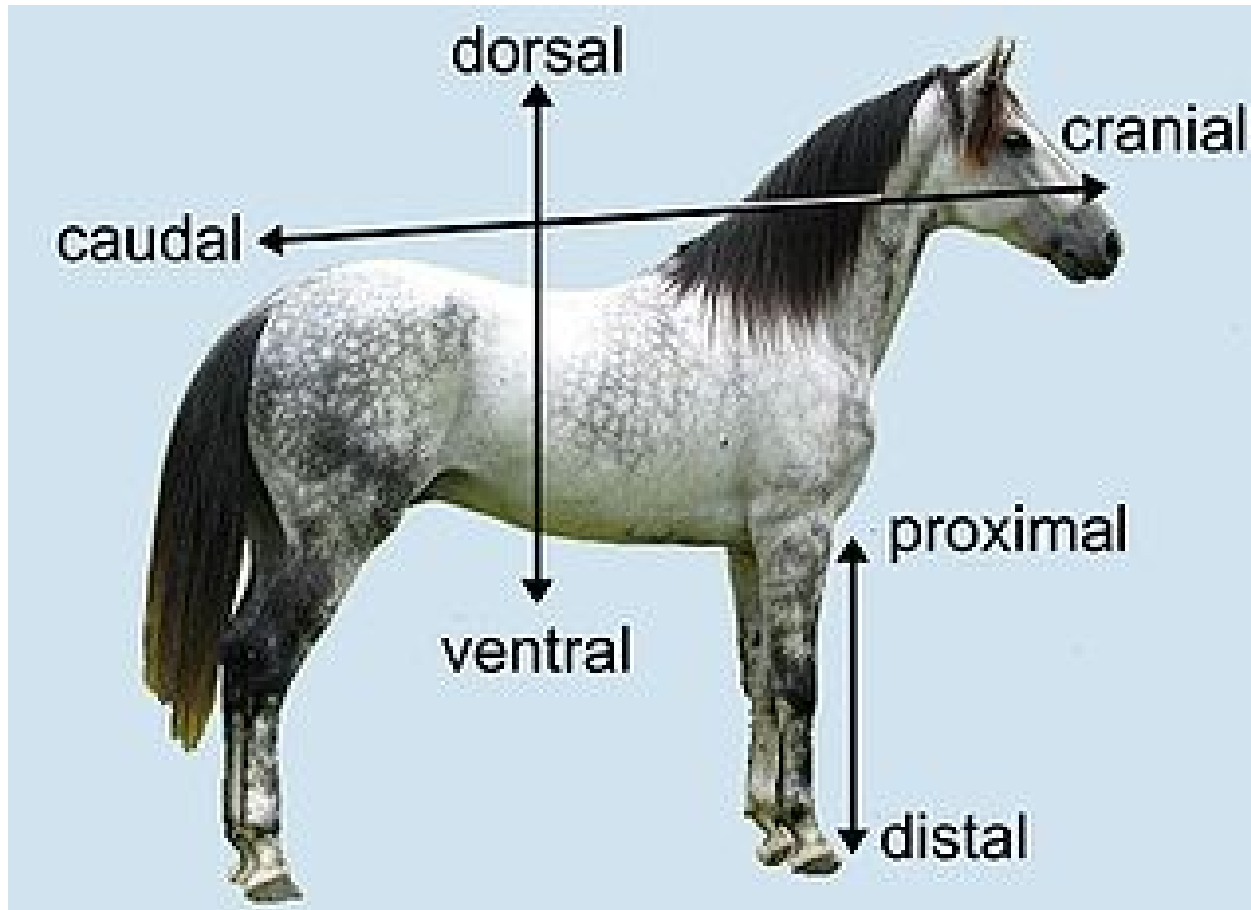
Farther from the origin of a body part or the attachment of a limb

Also not used to describe structures on the trunk of the body

(white arrows)

The shoulder is Proximal to the elbow while the wrist is Distal to the elbow.

Animal anatomical directions are somewhat different from humans

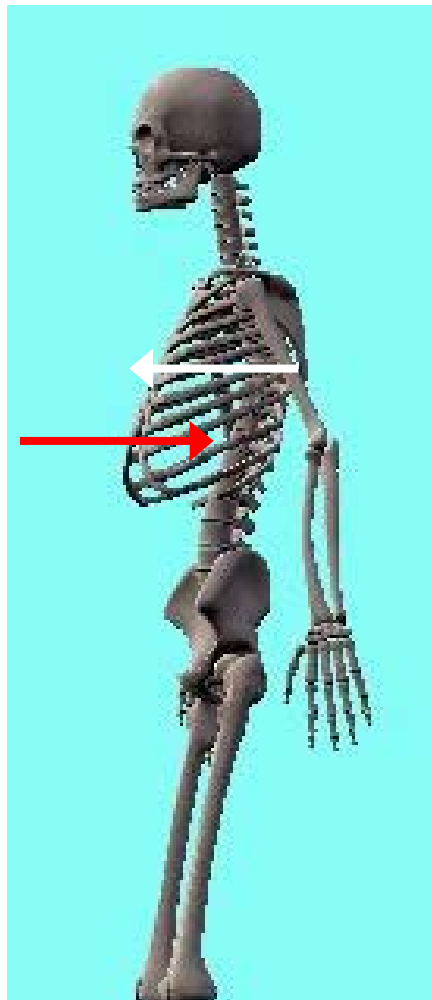


• The horse's eye's are Cranial and Ventral to its ears while its tail is Caudal and Dorsal to its belly.

Superficial

Outward or
more toward
the surface

(white arrow)



Deep

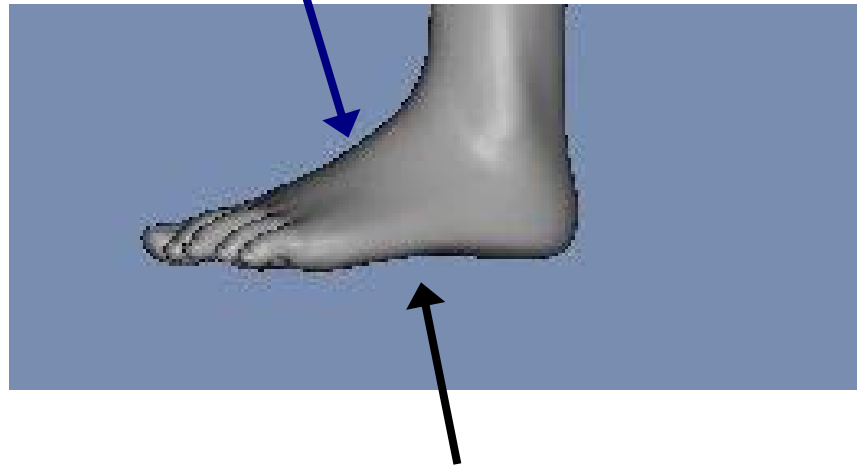
Inward or
more toward
the center of
the body

(red arrow)

The skin is Superficial to the ribs while the lungs are Deep to the ribs

Describing the foot requires an additional term

The top of the foot is dorsal to the plantar region of the foot



The sole of the foot is referred to as Plantar

The toenails are Dorsal to the plantar portion of the foot



Smart Links

These links can help you review or learn more about this topic

- Youtube video skeleton using anatomical directions

<http://www.youtube.com/watch?v=CHKFFgxxw1M>

- Quiz on planes and directions

<http://www.proprofs.com/quiz-school/story.php?title=identify-anatomical-planes-directions--human-body>

- Video animations on anatomical planes, directions, and regions

<http://www.youtube.com/watch?v=vhBRo1cMocA&feature=related>

(You must be in PPT slideshow view to click on links.)